University of North Dakota
UND Scholarly Commons

Physical Therapy Scholarly Projects
Department of Physical Therapy

2007

Rehabilitation of a 49 Year-Old Male Who Underwent a Right Knee Anterior Cruciate Ligament Reconstruction with Moderate to Severe Degenerative Joint Disease of the Left Knee

Roy W. Osborn
University of North Dakota

Follow this and additional works at: https://commons.und.edu/pt-grad
Part of the Physical Therapy Commons

Recommended Citation

Osborn, Roy W., "Rehabilitation of a 49 Year-Old Male Who Underwent a Right Knee Anterior Cruciate Ligament Reconstruction with Moderate to Severe Degenerative Joint Disease of the Left Knee" (2007). *Physical Therapy Scholarly Projects*. 507.
https://commons.und.edu/pt-grad/507

This Scholarly Project is brought to you for free and open access by the Department of Physical Therapy at UND Scholarly Commons. It has been accepted for inclusion in Physical Therapy Scholarly Projects by an authorized administrator of UND Scholarly Commons. For more information, please contact zeineb.yousif@library.und.edu.

REHABILITATION OF A 49 YEAR-OLD MALE WHO UNDERWENT A RIGHT KNEE ANTERIOR CRUCIATE LIGAMENT RECONSTRUCTION WITH MODERATE TO SEVERE DEGENERATIVE JOINT DISEASE OF THE LEFT KNEE

by

Roy W. Osborn, PT, MS, OCS
Bachelor of Science in Physical Therapy
University of North Dakota, 1977
Master of Science in Anatomy
University of Nebraska Medical Center, 1991

A Scholarly Project Submitted to the Graduate Faculty of the
Department of Physical Therapy
School of Medicine
University of North Dakota

in partial fulfillment of the requirements for the degree of

Doctor of Physical Therapy

Grand Forks, North Dakota
December, 2007

This Scholarly Project, submitted by Roy W. Osborn in partial fulfillment of the requirements for the Degree of Doctor of Physical Therapy from the University of North Dakota, has been read by the Advisor and Chairperson of Physical Therapy under whom the work has been done and is hereby approved.

(Graduate School Advisor)

(Chairperson, Physical Therapy)

PERMISSION

Title	Rehabilitation of a 49 year-old male who underwent a right knee anterior cruciate ligament reconstruction with moderate to severe degenerative joint disease of the left knee.
Department	Physical Therapy
Degree	Doctor of Physical Therapy

In presenting this Scholarly Project in partial fulfillment of the requirements for a graduate degree from the University of North Dakota, I agree that the Department of Physical Therapy shall make it freely available for inspection. I further agree that permission for extensive copying for scholarly purposes may be granted by the professor who supervised my work or, in his absence, by the Chairperson of the department. It is understood that any copying or publication or other use of this Scholarly Project or part thereof for financial gain shall not be allowed without my written permission. It is also understood that due recognition shall be given to me and the University of North Dakota in any scholarly use which may be made of any material in this Scholarly Project.

Signature(s) ____________________

____

____

____

Date ____________________

TABLE OF CONTENTS

LIST OF TABLES

ACKNOWLEDGEMENTS

This academic endeavor has been difficult and challenging for not only myself, but also for my wife, Betty. Betty has been extremely supportive and encouraging throughout these two years. Without her encouragement and patient support, it would not have been possible. In addition, the faculty at the University of South Dakota Physical Therapy Department have been encouraging and understanding as I have worked my way through these past two years. In addition, my dear friends Larry Job and Denise Stroud have been understanding and allowed me to "work" even though I was supposed to be "vacationing" with them on several occasions. A special thanks to my friends Tom Mohr, for his encouragement to begin this process, and to Gail Deyle for encouraging me to consider acquiring the DPT, even though he would have preferred I completed it at Rocky Mountain University of Health Professions

ABSTRACT

Background/purpose: Anterior cruciate ligament (ACL) rupture is reported to be one of the most common and most serious injuries among physically active individuals. There are a multitude of articles addressing rehabilitation following ACL reconstruction, but there is no clear "best method' identified in the evidence. Subjects with a combination of ACL rupture and degenerative joint disease are less frequent in occurrence, and also lack evidence to identify the most appropriate rehabilitation method.

Description: This case study provides the details of the first 8 weeks of rehabilitation for a 49 year old male subject who underwent anterior cruciate ligament reconstruction of one knee with moderate to severe degenerative joint disease of the contralateral knee.

Outcome: The subject was able to recover full range of motion of the anterior cruciate ligament reconstructed knee and was able to gain 10 degrees of flexion in the knee with degenerative joint disease within 4 weeks of right knee ACL reconstructive surgery. The subject was able to perform all ADL activities to include stairs without discomfort at 6 weeks post-op. Thigh girth at 15 cm above the medial joint line was equal at 8 weeks post-op. KT-1000 score indicated less than 1 mm difference at 8 weeks post-op.

Discussion: The rehabilitation program for this patients' ACL reconstructed knee followed a traditional, evidence based approach with modifications for patients age and

presence of degenerative joint disease in the contralateral knee. A combination of closed chain exercise, neuromuscular re-education and open chain exercises were used with this patient. The short-term results appear to be encouraging related to range of motion and muscle function. However, in this patients' case-as well as for other patients undergoing this procedure, the long-term (5 – 10 years) outcome is most important.

CHAPTER I

INTRODUCTION

In recreational athletes as well as in the organized sport athletic population, knee pain is quite common.[1] Pain that occurs as a result of traumatic knee injury (either contact or non-contact) may involve one of the ligaments in the knee. Mikkelsen, et al. state "the anterior cruciate ligament (ACL) rupture is reported to be one of the most common and most serious traumatic injuries among physically active individuals".[2] Following rupture of the ACL, the patient and physician must decide if surgery is the best option. The choice to undergo surgical reconstruction of the ligament is often recommended based on activity level. Jomha, et al. advocate "reconstruction of anterior cruciate ligament deficient knees before episodes of giving way occur in individuals intent on continuing activities that involve sidestepping and pivoting" due to the possibility for injury to other soft tissue structures about the knee.[3] The choices for the type of surgical procedure: bone-patellar tendon-bone vs hamstring tendon, appear to be the most recommended surgical options for patients today.[4] Dopriak, et al. indicate that if surgical reconstruction is selected, the bone patellar tendon bone procedure is the preferred method to reconstruct the knee among the orthopedic surgeons in their survey.[5]

The evidence for rehabilitation following anterior cruciate ligament reconstruction is less clear. Common deficits that potentially impact outcome following rehabilitation for patients who have undergone ACL reconstruction include loss of muscle mass of the quadriceps, range of motion deficits, and decreased neuromuscular control that may impact functional ability for various athletic performance tasks.[6] In a randomized controlled study, Risberg, et al. indicate the use of high intensity electrical stimulation combined with active exercise provides improved outcomes when compared to active exercise alone,[7] but there is little else reported in their review of literature that provides direction for rehabilitation. Trees et al. indicated the absence of any clear guidelines for exercise following ACL reconstruction in a review published in the Cochrane Data Base of Systematic Reviews.[8] The use of closed chain exercise as the only method of strengthening following ACL reconstruction has been advocated by several authors in the recent past. [9-11] However, Mikkelssen, et.al. indicate a combination of both open and closed chain exercise seem to provide the best increase in strength while still maintaining safety for the graft.[2]

Patients with a combination of ACL injury and ipsilateral degenerative joint disease who are candidates for surgical intervention occur at a very low frequency based on this authors experience. Williams, et al. describe the surgical management of patients in this category with either a routine ACL reconstruction or an osteotomy in combination with an ACL reconstruction to address any mechanical alignment deficits in combination with joint stabilization.[12] The patient who demonstrates degenerative joint disease of one knee with ACL rupture of the contralateral knee is also rare, and no literature was available at the time of this writing to guide the clinician. With respect to degenerative joint disease as the primary focus, Wu and Tuan discuss non-operative management of knee osteoarthritis (OA) related to exercise and weight loss, bracing and pharmacologic management, but did not go into any detail related to the exercise program. [13] Two studies conducted by Deyle, et al. have shown positive effects on knee function in the short term (up to one year) when a comprehensive manual therapy approach is utilized with subjects who have documented degenerative joint disease (DJD) of the knee without surgical intervention.[14,15]

The purpose of this case review is to examine the rehabilitation program and the progress of a male individual who has undergone ACL reconstruction of one knee, and also has moderate to severe DJD in the contralateral knee.

CHAPTER II

CASE DESCRIPTION

Examination, Evaluation and Diagnosis

The subject who is the focus of this case study is a 45+ year-old male who is a local entrepreneur. He is an avid skier and skiing coach who has been skiing since approximately age 16. As he grew older, he became increasingly involved in ski racing, to include coaching ski racing. He has maintained that interest throughout his adult life.

However, his interest in skiing has come at a price. He has sustained several injuries throughout his skiing career. His initial injury occured at age 11 when he sustained a left forearm fracture and a right tibia-fibular fracture. At age 17 he sustained his first ski related injury when he jumped over a fence while skiing. He indicates he landed "wrong" and twisted his left knee. He subsequently underwent a left knee total meniscetomy. Ghosh, et al. have shown that total menisectomy leads to early degenerative change of the knee due to increased joint loading in an animal model.[16] Renstrom and Johnson indicate that total excision of a meniscus causes a 2.5 times increase in load per unit area at the knee joint. [17] Typically, surgeons do not remove the entire meniscus today unless it has been damaged beyond repair, because they attempt to salvage as much of the meniscus as possible to preserve joint integrity for the reasons noted above.

Following the meniscal excision surgery on his left knee he noted progressive stiffness of this knee over the following years. He underwent a left knee diagnostic arthroscopy in 2001 to asses the joint and perform a "lavage" of the joint. This has been shown to be of some benefit for some patients according to Edelson, et al.[18] During this diagnostic arthroscopy he was found to have significant osteoarthritis of his left knee, and was advised by his orthopedic surgeon that he will require a total joint arthroplasty in the not too distant future. D'Ambrosia has indicated that "osteoarthritis is the most common joint disease causing disability, affecting more than 7 million people in the United States". [19]

Since the most recent left knee arthroscopy, the patient in this case report has consistently used Synvisc injections for his left knee over the past 4-5 years. He usually receives the Synvisc injection prior to ski season. Synvisc is an injectable substance that is referred to as a viscosupplementation for the joint. Synvisc has been shown to be an "effective treatment for OA of the knee with beneficial effects: on pain, function and patient global assessment; and at different post injection periods but especially at the 5 to 13 week post injection period" according to Belamy, et al. [20] Subjectively, this patient indicates he has a constant low level ache in his left knee in the 1-2 out of 10 range with 0 being no pain and 10 being worst pain imaginable. This knee becomes more sore with increased activity, and he occasionally has problems with swelling.

His most recent injury also involved skiing. He was racing on Thanksgiving day in 2004 when he twisted his right knee. He was diagnosed with an injury to his anterior cruciate ligament. Examination to detect ACL tear can be somewhat challenging with all the possible special tests that have been described (Lachman, anterior drawer, slocum, losee, pivot shift). These tests can be divided into those that are sagittal plane tests (Lachman and anterior drawer) and those that are assessments for rotary instability

(Slocum, McIntosh, pivot shift, Losee), as decribed in Magee.[21] As a clinician, it is important to select the special test that is most reliable (i.e. has the highest sensitivity and specificity), since this finding may lead to operative intervention. The Lachman test has been shown to have a sensitivity of 80-98% and a specificity of 95% as opposed to the anterior drawer, which has a sensitivity of 22-41% and a specificity of 97% in a review of the original test description performed by Malanga et.al. [22]

Following the injury on Thanksgiving day in 2004, he continued to ski with the use of a brace, but continued to have difficulty with his knee feeling "loose". As a result, he underwent right knee bone patellar tendon bone ACL reconstruction on December 28, 2005. Following this surgery, he was shown how to perform range of motion and quad setting exercises and used a continuous passive motion (CPM) machine at home. He was initially seen as an outpatient in the physical therapy department on January 11, 2006 (2 weeks post-operation). He described his right knee pain as an ache and identified the level of pain as a 2-3 out of 10 with 0 being no pain and 10 being worst pain imaginable.

At the initial visit to physical therapy, the patient was ambulatory to the physical therapy department without any assistive devices. He was wearing a post-operative brace on his right leg with the brace locked at 0 degrees for ambulation and sleep. His surgical wound (anterior knee) was healing well and there was no drainage from the wound. He had a 1-2+ effusion present. He was able to perform a fair static quadriceps contraction (i.e. the medial and lateral heads of the quadriceps were visible with static contraction, but the tone was significantly different from the left). His knee range of motion for this initial visit is listed in Table 1. He demonstrated the ability to transfer from stand to sit to supine and back to stand without difficulty. He demonstrated acceptable quadriceps control by being able to perform a straight leg raise in his brace without difficulty. Assessment of gastrocnemius muscle length on the left indicated he was only able to dorsiflex his foot 10 degrees with knee in full extension, but he was able to dorsiflex to 15-20 degrees with his knee flexed. Prone knee extension demonstrated decreased passive knee extension bilaterally (Table 1).

Table 1: Initial knee joint range of motion findings on examination

KNEE	ACTIVE FLEXION	PASSIVE EXTENSION
*R	120	3
L	125	5

* operated side

The patient was evaluated as status post right knee anterior cruciate ligament reconstruction with decreased quadriceps function and decreased range of motion of his right knee. He also has decreased range of motion of his left knee with deceased length of his left gastrocnemius and posterior capsule of his left knee.

The patient's diagnosis (per Guide to Physical Therapist Practice [23]) for the right knee was Pattern 4I: Impaired Joint Mobility, Motor Function, Muscle Performance, and Range of Motion Associated with Bony or Soft Tissue Surgery. For the left knee - Pattern 4D: Impaired joint Mobility, Motor Function, Muscle Performance, and Range of Motion Associated With Connective Tissue Dysfunction.

Prognosis and Plan of Care

The prognosis for return to pre-injury level of function involving repetitive loading activities of his lower extremities is poor for this patient based on his age, the presence of moderate to severe degenerative joint disease in the left knee and the presence of degenerative joint disease in his right knee at the time of surgery. The prognosis for recovery of full right knee range of motion, improved range of motion of the left knee, performance of low or no-impact loading activities and the ability to perform routine activities of daily living is very good based on patient's motivation and physical condition prior to surgery.

The plan of care for skilled physical therapy was deemed necessary to restore both right and left knee range of motion and right thigh musculature. This involved a comprehensive home and clinic exercise program to achieve optimal results. It was anticipated the patient would need to be seen for 2-3 times per week for 5-8 weeks.

Intervention

This patient was provided with both written and verbal home exercise program instruction consisting of stretching for his right and left hamstring musculature and right and left gastrocnemius musculature 2x daily. He was also shown how to perform static quadriceps contraction 3-5 times per day. The contraction was performed by first performing knee flexion to 80-90 degrees, then extending his knee by sliding his heel along the bed until his knee was straight – then performing a static quadriceps contraction, as has been suggested by Gail Deyle (personal communication). He was advised to perform a straight leg raise on the left in combination with this activity, but to not do the SLR on the right due to lack of quadriceps control and possible compromise of the graft.

He was also shown how to perform supine active knee flexion followed by using a towel for overpressure at the proximal tibia to assist posterior tibial glide during end of range knee flexion motion. He was advised to perform this activity on both the right and left sides. He was also shown how to perform prone knee hangs (passive extension) off the end or side of a bed to assist in recovering terminal knee extension on the right, and was also advised this would be appropriate to also perform on the left.

Clinic care consisted of manual therapy utilizing Grade II-Grade IV posterior glides of tibia on femur as suggested by Edmunds, to restore full knee flexion on the right and to increase knee flexion on the left.[24] Manual therapy was also performed to restore right knee terminal extension utilizing techniques described by Edmunds with slight modification to protect the ACL graft.[24] Manual therapy that addressed the posterior capsule of the left knee was also included in an attempt to improve left knee extension range of motion utilizing techniques described by Deyle, et al. [14] The method employed with this patient to enhance tibial external rotation of the right knee is as follows: the patients' knee is placed in 5-10 degrees of flexion in supine, and the tibia is externally rotated several times by providing a superior and laterally directed force on the posterior/proximal portion of the medial tibial plateau while a simultaneous posteriorly directed force is applied to the anterior-lateral proximal tibia to minimize anterior translation of the tibia on the femur. Following several repetitions of this activity, the patient is then asked to perform knee flexion followed by terminal knee extension coupled with a static quadriceps contraction. While the subject performs the terminal extension component, the clinician assists the lateral rotation of the tibia utilizing the hand placement and force application described above. This technique is often most effective following passive terminal knee extension in supine with the hip in extension and the foot in neutral to isolate the connective tissue stretch to the posterior capsule of the knee. The safety of this method is demonstrated by the KT-1000 results in Table 3.

This patient also performed a variety of closed chain activities as suggested in past studies to restore quadriceps function with minimal risk to the graft. [2, 9-11] He began by performing single leg stance activities on January 16, 2006 (19 days post-op). Arm perturbations were added to the single leg stance on this date as well. On this same date, the patient performed forward lunges (pain free) with knee flexion as tolerated, forward step-ups onto 4 inch step, throwing weighted ball into pitchback while in single leg stance on floor, double-leg leg press with 105# and single leg leg press with 60# on the operated side. The closed chain activities were progressed as tolerated over the course of the next 4 weeks. Attempts at performing mini-squats were painful on the right, so they were not included in the rehabilitation program. Patient progressed to single leg stance on an Airex® pad on January 20 (23 days post-op) to further stress his neuromuscular system (i.e. proprioception) as has been suggested in previous research. [25, 26] He also performed backward walking on a treadmill based on work performed by Cipriani, et.al. [27] Treadmill elevation for this backward walking activity ranged between 5% and 15% elevation with speeds in the 2.0 to 2.5 mph range and durations of 2-4 minutes. Resisted hip extension in standing and prone hamstring strengthening were also included early (2 weeks post-op) in the rehabilitation program and progressed as he was able.[28] Hip extension is included in this subjects rehabilitation due to the influence of the hip extensors on knee function through the iliotibial band/gluteus maximus relationship. The method this activity is performed permits the hip extensors to be exercised on the operated side without any stress on the graft. This is accomplished by using a standing hip extension machine in which the individual places the posterior surface of the thigh on a pad with the hip in 90 or more degrees of hip flexion – the knee is relaxed with the knee in flexion. The contralateral limb supports the weight of the body and stabilizes the trunk for the movement. The subject then extends the hip against a resistance. This activity is performed on both lower extremities. The operated leg is providing stance support when the non-operated leg is performing this exercise, which may also assist quadriceps function in a closed chain mode. The amount of resistance is adjusted for the individual.

Hamstring strengthening is felt to be vital for patients who have undergone ACL reconstruction, because the hamstrings are an ACL protagonist as suggested by Renstrom et.al. [26] This patient performed hamstring strengthening in the prone position – this places the least amount of strain on the graft due to both the prone position as well as control of both the flexion and extension portions of the arc of motion is through the hamstrings as suggested by Renstrom et al. This patient performed double leg hamstring curls initially followed by single leg hamstring curls with the number of repetitions per set being no less than 15, and two sets for double leg and single leg hamstrings (i.e. 6 sets total). There is no known evidence to support this method of hamstring strengthening. The American College of Sports Medicine exercise guidelines suggest 8-12 repetitions performed for 2-3 sets with the intensity at 80% of 1 repetition maximum are necessary to increase strength. Due to the operative procedure and the degenerative joint disease, a single repetition maximum was not attempted for this subject.

This patient began performing an independent strengthening program for hip extension, hamstrings, leg press and calves beginning on January 23, 2006 (26 days post-op). This permitted the subject to be seen for therapy that focused on range of motion, neuromuscular control activities and functional activities, permitting the patient to perform his strength program at his convenience (a necessity due to his work schedule). Open chain quadriceps strengthening was added when the subject was 8 weeks post-op as recommended by Mikkelsen, et.al. [2]

Outcomes at Discharge

The patient was seen for a total of 12 visits in physical therapy. The patient expressed great satisfaction with the progress he made during the course of his rehabilitation. At the time of his last scheduled physical therapy visit he was able to perform all ADL's without discomfort in either knee to include climbing up and down stairs. He has decided that downhill ski racing is no longer an option for him due to the degenerative changes in his left knee and the risk of re-injury to his right knee. He will, however, continue to ski recreationally, and will continue to coach ski racing. He has indicated he is investigating endurance cycling as a physical outlet in the future. Table 2 identifies the changes in range of motion during the course of care. Table 3 identifies the results of arthropometric testing for knee stability.

Table 2: Range of motion progression from initial visit until 8 weeks post-operative.

DATE	*R KNEE ACTIVE FLEXION	L KNEE ACTIVE FLEXION	*R KNEE PASSIVE EXTENSION	L KNEE PASSIVE EXTENSION
11Jan06	120	125	3	5
20 Jan 06	137	Not available	0	Not available
3 Feb 06	142	136	2 hyperext	3
25FEB06	145	135	2 hyperext	2

* operated side

Table 3: Knee stability assessment per KT-1000+ 8 weeks post-operative.

	Average of 3 measures at 15#	Average of 3 measures at 20#
*Right	2.5 mm	3.2 mm
Left	1.8 mm	2.4 mm
Difference	0.7 mm	0.8 mm

* operated side

+ Manual max not performed since this subject was only 2 months post-op at the time these measures were collected.

Thigh girth measurements performed at 8 weeks post-op indicated the right and left were equal at 43.5 cm. Measurements were taken at 15cm above the medial joint line bilaterally. The patient had a persistent trace effusion at 8 weeks post-op. This was felt to be due to degenerative joint disease within the right knee. Quadriceps tone on the right was felt to be nearly equal to the left at 8 weeks post-op.

CHAPTER III

DISCUSSION/REFLECTION

The patient in this study has had excellent subjective and objective results at the time the data was collected. However, no standardized subjective/outcome questionnaires or functional testing results are available for this subject. The rehabilitation of this subject has been strongly influenced by evidence related to ACL rehabilitation. ACL rehabilitation for both the post-operative and the non-operative patient is extremely complex and requires clarification and discussion on several topic areas as it relates to this patient's rehabilitation.

Due to the wide variety of variables that potentially impact ACL reconstruction surgery (isolated ACL tear vs combined ACL injury with meniscus tear or posterior cruciate ligament injury, medial collateral ligament injury, preexisting collagen deformity, diminished proprioceptive performance, bony injury, vascular injury, etc.), there are many components of a rehabilitation program that must be individualized, making it difficult for any one article to cover all the possibilities seen clinically. Other variables that may affect the rehabilitation and the outcome include: the facility in which the rehabilitation is being performed, the experience level of the clinician, as well as the equipment available to the clinician and the patient. As has been noted previously, despite all of the available evidence, there does not appear to be any one specific rehabilitation program that works best following anterior cruciate ligament reconstruction. Mikkelsen, et.al. [2] point out that the difficulty in recovering quadriceps muscle torque generation ability for patients who have undergone ACL reconstruction may be related to the recent emphasis on exclusive closed chain exercise programs. As a result of this emphasis on closed chain exercise, many clinicians have not incorporated open chain exercise for the quadriceps muscles when conducting rehabilitation for patients who have had an ACL reconstruction surgery.[11]

Although there is considerable information in the literature about the rehabilitation of patients who have undergone an ACL reconstruction, no specific links have been established between early knee range of motion and ultimate outcome. The progression of range of motion for the patient in this case study is similar to other patients with this surgical procedure who have been managed following ACL reconstruction within this facility by the author in the past two years. This subject's right knee range of motion at 2 months post-op indicates he has full range of motion based on guidelines in Norkin and White. [25] Full knee range of motion is felt to be important for normal knee function. The change (improvement) in left knee range of motion that occurred during this period of rehabilitation should assist with activities of daily living and his other recreational pursuits. Hopefully this improvement of left knee function will translate into being able to postpone this patients left total knee arthroplasty surgery, as was found in the study by Deyle, et.al. [15] However, this will not be known for several months in the future.

The concept of terminal knee extension and the feeling of being able to "lock" the knee is felt by the author to be important for overall knee function, although there is no report of this relationship in the literature. The patient in this study was able to describe the sensation of feeling his right knee "lock" when performing terminal knee extension three weeks after his surgery. From personal experience, patients are frequently not able to feel their knee "lock" after ACL reconstruction surgery for several months, if ever. It is possible that this is a mechanical finding, but passive terminal knee extension that matches or exceeds the non-operated leg would not explain a mechanical loss of the ability to feel the knee "lock" in terminal extension. It is possible that terminal knee extension mechanisms have been disrupted – specifically, the ability to externally rotate the tibia near full extension. The rehabilitation approach utilized in this case to address this problem has focused a portion of the intervention on restoring the ability of the subject to feel the knee "lock" in place with terminal knee extension. The methods to be described have had very good success restoring this ability with patients who have undergone this surgery in the past. The closed chain activities such as forward lunges, forward step-up and side step-up activities described above are felt to be important in patients who have undergone ACL reconstruction to condition the remaining patellar ligament, rather than as a strengthening effect. Patellar ligament conditioning is assumed to be the major effect of these activities, since there have been no studies to date that have indicated an increase in quadriceps strength following closed chain exercise using step-ups and theraband. In this authors experience, the incorporation of step-ups onto a 4 to 6 inch step (pain free) in both forward and side-step at a moderate speed and for 6-12 minutes non-stop, has been successful in decreasing anterior knee pain in post-operative ACL patients when combined with transverse friction massage of the patellar ligament.

Backward walking on a treadmill is felt to be very important to gain quadriceps activation in a functional activity. Equal loading through the lower extremities is felt to be very important during this activity to maximize quadriceps activation, so emphasis is placed on weight transfer onto the operated leg during stance phase, which is difficult for these patients to accomplish. This activity creates considerable loading of the anterior knee/patellar ligament, so the subject should be able to easily perform forward and side step ups onto a 6 inch step with good weight transfer onto the operated side prior to performing this activity at higher elevations. It is important that any anterior knee pain be addressed by decreasing the amount of knee flexion, slowing the treadmill speed down or decreasing the elevation – or a combination of all components.

The incorporation of open chain leg extension through a limited arc of motion is felt to be vital for recovery of quadriceps strength and mass. The initial open chain leg extension exercise session at 6-8 weeks post-op, is an attempt to determine the ability of the subject to perform this activity, since it may be uncomfortable for some patients. Therefore, the weight is kept very light, and the range of motion is controlled (90-60 degrees) to ensure the amount of shear that could possibly create unwanted tension on the graft is minimized based on findings by Renstrom, et.al. [26] If the subject is unable to perform this activity in a concentric/isotonic fashion, an attempt at eccentric strengthening is performed. If this also causes pain, then isometric contractions in a pain free portion of the range (90-60 degrees) are performed. The patient performs high repetitions (50-70 per set x 2) until fatigue is felt in the quadriceps.

The rehabilitation of this patient with a combination of ACL reconstruction and DJD is somewhat unique today. However, as the "baby boomer" generation ages, patients with similar knee findings may become more frequent. The rehabilitation for this patient who has undergone ACL reconstruction is multifaceted and is based on existing evidence. The short-term results appear to be encouraging related to range of motion and muscle function. However, in this patients' case-as well as for other patients undergoing this procedure, the long-term (5 – 10 years) outcome is most important.

Reflective Practice

Clinical decision algorithms were developed for future clients with similar pathologies after an extensive review of the literature.

Appendix A (page 29) presents the clinical decision tree for examination of a patient with knee injury with the presence of knee effusion. Appendix B (page 30) presents the clinical decision tree for intervention of a patient with knee DJD. Appendix C (page 31) presents the organizational plan of post operative rehabilitation activities following ACL reconstruction.

Application to Future Cases:

In this particular case the patient had undergone surgical reconstruction of his knee. The history portion of the examination was adequate for this patient. Additional questions that can also be included would include questions related to current medications, and any medical conditions that might affect rehabilitation. If I was seeing a patient who had not had surgery, I would ask specific questions related to the mechanism of injury, the length of time it took for the swelling to occur, whether the swelling had changed since the index injury, any history of previous knee injury, the presence of any additional areas of soreness in the knee or any other area of the body.

In this particular case, assessing the ability to contract the quadriceps, the ability to flex and extend the knee, the ability to perform leg raising with the knee in full extension, the amount of swelling (can be measured at mid-patella), the appearance of the surgical wound and any other findings related to the surgery (ecchymosis, abrasions, etc) were important components and will be retained when examining patients with this condition in the future. In addition, the ability to independently put on the brace properly is important. Assessment of muscle length for the quadriceps, hamstrings and hip musculature would assist when designing a flexibility program. If the patient had not had surgery, performance of ligamentous testing of the major stabilizing ligaments for medial-lateral as well as anterior-posterior stability to include rotary stability testing would be important. In addition, palpation for tenderness in various locations (joint line, patellar ligament, patellar retinaculum) would be important.

The plan of care for the current patient attempted to address swelling, muscle control, neuromuscular control, muscle length, strengthening and joint range of motion. Changes to the plan of care that may be incorporated would be the use of electrical stimulation in an attempt to decrease the amount of knee swelling. Knee swelling inhibits quadriceps muscle function, so any decrease in knee swelling would theoretically improve quadriceps muscle function.

It is important to continue to update on high quality evidence related to rehabilitation of patients who have undergone ACL reconstruction. Also conducting reviews of strength literature may help gain additional perspective on various methods of performing strengthening, which may apply to patients who have undergone ACL reconstruction.

The skills required to supervise/guide this patient in his rehabilitation were within the realm of physical therapy practice and therefore I would personally not refer this patient out.. However, there exists the possibility to seek other disciplines to assist patients with this surgical procedure (see comments in "Cost of physical therapy" section directly below).

Cost of Physical Therapy

The overall billed amount for this patient's rehabilitation was approximately \$2400.00 for 12 visits. The number of visits can be reduced with judicious use of each session, and engaging the patient in the rehabilitation process as a partner with periodic follow-ups and progression. The billed amount for each 15 minute period at this facility is high relative to independent therapist practice in this same community, which also affects the total amount billed. In this institution, the individual therapists are not involved in the fees charged for services, as therapists in independent practice settings are. When looking at the total cost for the surgery and rehabilitation in light of the outcomes, I would state that the cost was reasonable (albeit, on the high end) for a patient with a combination of ACL reconstruction of one knee with DJD of the other knee.

It may be possible to reduce the visits (and thus, the overall billed amount) by seeing the patient for 2-3x per week for the first 2 weeks to ensure they don't have any problems immediately post-op. The patient can then be placed on a 1x per week re-check and program update for the next 2 weeks, and then once every 2 weeks for the next month. In addition, the patient can be shown how to perform machine weight strengthening and treadmill walking/riding and use of an exercycle to maintain aerobic capacity. The patient can perform these activities in a local gym or health club. It may be beneficial to have the patient work with an exercise specialist in a local health club/gym (assuming the specialist is aware of the surgery performed and has been advised which activities the patient is NOT to perform to ensure the patient does not compromise the graft). Athletes attempting to return to sport participation may require closer supervision, and coordination with the athletes athletic trainer concerning rehabilitation would be most beneficial. It is very difficult to keep the number of visits under 12 for athletes attempting to return to sport following ACL injury without risking re-injury as the athlete progresses through the more complicated functional phases of rehabilitation.

Influence on Professional Development

The rehabilitation of individuals who have undergone ACL reconstruction has been an area of interest for me for the past 20 years. I am currently involved in the re-design of a comprehensive rehabilitation program that incorporates physical therapy, athletic training, and performance enhancement for athletes attempting to return to sport participation at our facility. We will be conducting a prospective research project based on the updated (evidence based) protocol. In addition, we will be conducting a retrospective review of individuals who have undergone ACL reconstruction in the past 5 years as well. I have developed a line of scholarly activity as part of my faculty line of scholarship that links to ACL rehabilitation. I am currently involved in conducting a review of the literature pertaining to the application of closed kinetic chain exercise in strengthening the quadriceps femoris musculature.

APPENDIX

APPENDIX A

CLINICAL DECISION TREE FOR ACUTE KNEE INJURY WITH EFFUSION

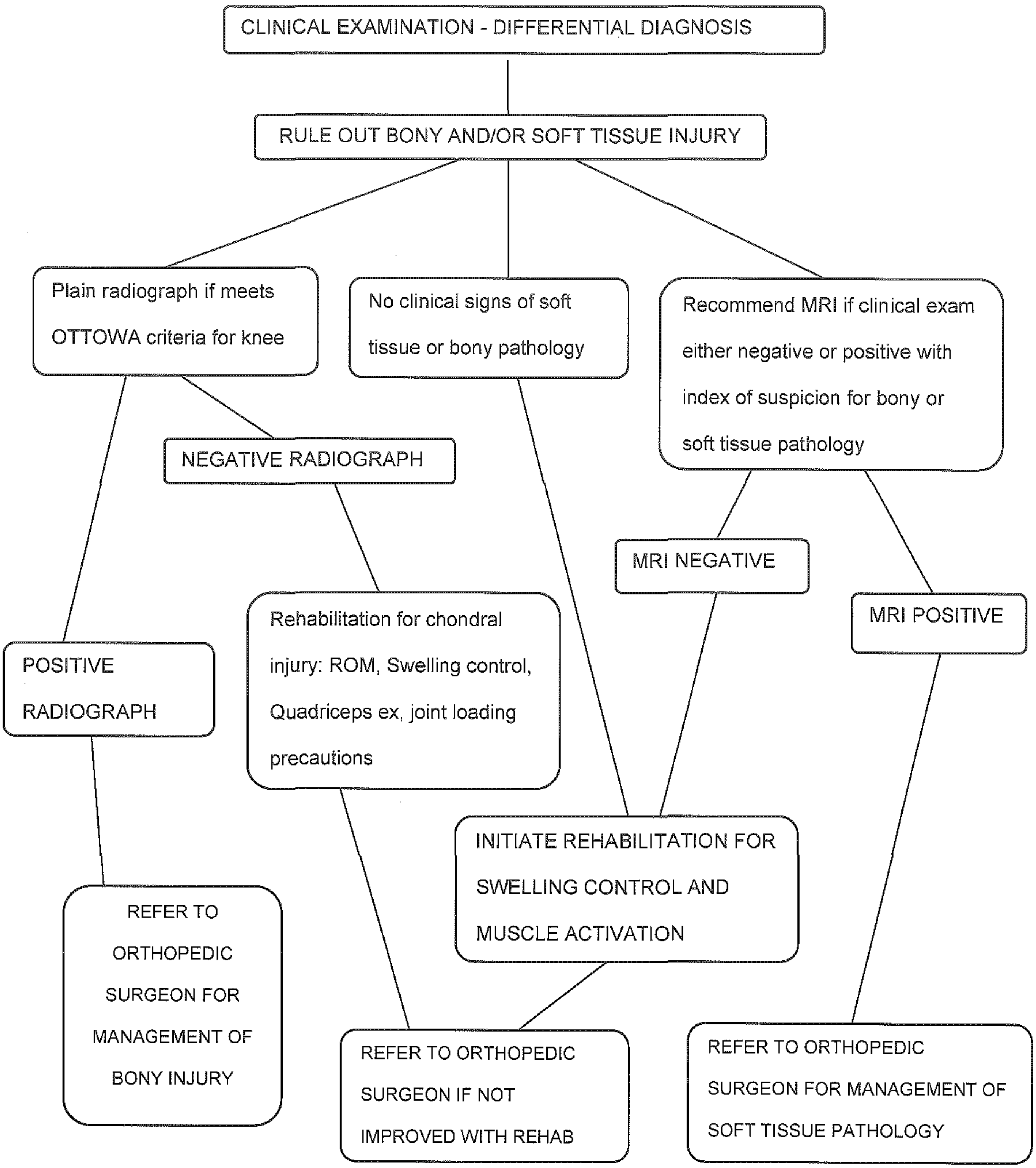

APPENDIX B

CLINICAL DECISION TREE FOR INTERVENTION: KNEE DJD

APPENDIX C

INTERVENTION: POST-OP ACL RECONSTRUCTION

PATIENT WHO HAS UNDERGONE BPTB OR HS ACL RECONSTRUCTION

ACUTE/PROTECTION PHASE (STARTS IMMEDIATELY)

ADDRESS SWELLING AND MUSCLE CONTROL. BEGIN QUADRICEPS MUSCLE ACTIVATION INCLUDING SLR

RECOVER KNEE JOINT RANGE OF MOTION – MAY USE STATIONARY BIKE

PERFORM RESISTED STRENGTHENING FOR HIP EXTENSORS, HAMSTRINGS, CALF MUSCULATURE (Pt WITH HS GRAFT WAITS 2 WEEKS FOR RESISTED HS)

INITIATE NEUROMUSCULAR ACTIVATION/CONTROL

FUNCTIONAL PHASE (STARTS AT APPROXIMATELY 6 WEEKS POST-OP)

ADDRESS ANY RANGE OF MOTION DEFICITS

CONTINUE STRENGTHENING USING HIGHER WEIGHTS AND LOWER REPS (PAIN FREE)

IF NOT ALREADY PERFORMING OPEN CHAIN QUADS, INITIATE – KEEP ROM BETWEEN 90-60

ADVANCE THE NEUROMUSCULAR ACTIVATION TO INCLUDE PLYOMETRICS AND SPORT SPECIFIC CUTTING DRILLS

BEGIN FORWARD RUNNING IN A STRAIGHT LINE – PROGRESS TO SHALLOW CUTTING MANEUVERS AND PROGRESS TO SHARP HIGH SPEED CUTTING MANEUVERS AND SPORT SPECIFIC FUNCTIONAL DRILLS

REFERENCES

1. Calmbach WL, Hutchens M. Evaluation of Patients Presenting with Knee Pain: Part 1. History, Physical Examination, Radiographs, and Laboratory Tests. *American Family Physician*. 2003;68:907-912.

2. Mikkelsen C, Werner S, Eriksson E. Closed kinetic chain alone compared to combined open and closed kinetic chain exercises for quadriceps strengthening after anterior cruciate ligament reconstruction with respect to return to sports: a prospective matched follow-up study. *Knee Surg Sports Traumatol, Arthrosc*. 2000; 8:337-342.

3. Jomha NM, Borton DC, Clingeleffer AJ, Pinczewski LA. Long Term Osteoarthritic Changes in Anterior Cruciate Ligament Reconstructed Knees. *Cl Orthop and Rel Res*. 1999; 358:188-193.

4. Biau DJ, Toumoux C, Katsahian S, Schranz PJ, Nizard RS. Bone-patellar tendon-bone autografts versus hamstring autografts for reconstruction of anterior cruciate ligament: meta-analysis. *BMJ*. 2006;332:995-1001.

5. Dopirak RM, Adamany DC, Steensen RN. A Comparison of Autogenous Patellar Tendon and Hamstring Tendon Grafts for Anterior Cruciate Ligament Reconstruction. *Orthopedics*. 2004. 27:8:837-844.

6. Myer GD, Paterno MV, Ford KR, Quatman CE, Hewett TE. Rehabilitation After Anterior Cruciate Ligament Reconstruction: Criteria-Based Progression Through the Return-to-Sport Phase. *JOSPT*. 2006;36:385-402.

7. Risberg MA, Holm I, Steen H, Ekiksson J, Ekeland A. The effect of knee bracing after anterior cruciate ligament reconstruction. A prospective, randomized study with two years' follow up. *Am J Sports Med*. 1999. 27:1:76-83.

8. Trees AH, Howe TE, Dixon J, White L. Exercise for treating isolated anterior cruciate ligament injuries in adults. *Cochrane Database of Systematic Reviews*. 2006.

9. Bynum EB, Barrack RL, Alexander AH. Open Versus Closed Chain Kinetic Exercises After Anterior Cruciate Ligament Reconstruction: A Prospective Randomized Study. *Am J Sports Med*. 1995; 23:401-406.

10. Kvist J, Gillquist J. Sagittal Plane Knee Translation and Electromyographic Activity During Closed and Open Kinetic Chain Exercises in Anterior Cruciate Ligament-Deficient Patients and Control Subjects. *Am J Sports Med.* 2001; 29:72-82.

11. Yack HJ, Collins CE, Whieldon TJ. Comparison of closed and open kinetic chain exercise in the anterior cruciate ligament-deficient knee. *Am J Sports Med.* 1993; 21:49-54.

12. Williams RJ, Wickiewicz TL, Warren RF. Management of Unicompartmental Arthritis in the Anterior Cruciate Ligament-Deficient Knee. *Am J Sports Med.* 2000; 28:749-760.

13. Wu SS, Tuan K. Current Concepts in Nonoperative Management of Knee Osteoarthritis. *Orthopedics.* 2005; 28:134-139.

14. Deyle GD, Henderson NE, Matekel RL, Ryder MG, Garber MB, Allison SC. Effectiveness of Manual Physical Therapy and Exercise in Osteoarthritis of the Knee: A Randomized, Controlled Trial. *Annals of Int Med.* 2000;132:173-181.

15. Deyle GD, Allison SC, Matekel RL, Ryder MG, Stang JM, Gohdes DD, Hutton JP, Henderson NE, Garber MB. Physical Therapy Treatment Effectiveness for Osteoarthritis of the Knee: A Randomized Comparison of Supervised Clinical Exercise and Manual Therapy Procedures Versus a Home Exercise Program. *Phys Ther.* 2005;85:1301-1317.

16. Ghosh P, Sutherland J, Bellenger C, Read R, Darvodelsky A. The Influence of Weight-Bearing Exercise on Articular Cartilage of Menisectomized Joints: An Experimental Study in Sheep. *Clin Ortho Rel Res.* 1990;252:101-113.

17. Renstrom P, Johnson RJ. Anatomy and Biomechanics of the Menisci. *Clinics in Sports Med.* 1990;9:523-538.

18. Edelson R, Burks RT, Bloebaum RD. Short-Term Effects of Knee Washout for Osteoarthritis. *Am J Sports Med.* 1995;23:345-349.

19. D'Ambrosia RD. Epidemiology of osteoarthritis. *Orthopedics.* 2005;28:S201-S208.

20. Bellamy N, Campbell J, Robinson V, Gee T, Bourne R , Wells G. Viscosupplementation for the treatment of osteoarthritis of the knee. *The Cochrane Database of Systematic Reviews.* 2006:1.

21. Magee D. Orthopedic Physical Assessment. 4th Ed.

22. Malanga GA, Andrus S, Nadler SF, McLean J. Physical Examination of the Knee: A Review of the Original Test Description and Scientific Validity of Common Orthopedic Tests. *Arch Phys Med Rehabil.* 2003;84:592-603.

23. Guide to Physical Therapist Practice. 2nd ed. *Phys Ther.* 2001. 81:1:9-744.

24. Edmunds SL. *Manipulation and Mobilization: Extremity and Spinal Techniques.* St. Louis, MO: Mosby-Year Book, Inc.: 1993.

25. Risberg MA, Mork M, Henssen HK, Holm I. Design and Implementation of a Neuromuscular Training Program Following Anterior Cruciate Ligament Reconstruction. *J Ortho Sports Phys Ther.* 2001. 31:11:620-631.

26. Iwasa J, Adachi N, Tobita M, Katsube K, Uchio Y. Proprioceptive Improvement in Knees With Anterior Cruciate Ligament Reconstruction. *Cl Orthop Rel Res.* 2000. 381:168-176.

27. Cipriani DJ, Armstrong CW, Gaul S. Backward Walking at Three Levels of Treadmill Inclination: An Electromyographic and Kinematic Analysis. *J Orthop Sports Phys Ther.* 1995. 22:3:95-102.

28. Shultz SJ, Perrin DH. The Role of Dynamic Hamstring Activation in Preventing Knee Ligament Injury. *Athletic Ther Today.* 1999:4:3:49-53.

29. Norkin CC, White DJ. Measurement of Joint Motion: A Guide to Goniometry. 2nd ed. Philadelphia, PA. F.A. Davis Company: 1995.

30. Renstrom P, Arms SW, Stanwyck TS, Johnson RJ, Pope MH. Strain within the anterior cruciate ligament during hamstring and quadriceps activity. *Am J Sports Med*. 1986. 14:1:83-87.