



2019

Benefits of 3D Breast Tomosynthesis Combined with 2D Digital Mammography in Screening Women for Breast Cancer

Danielle M. Swanson
University of North Dakota

[How does access to this work benefit you? Let us know!](#)

Follow this and additional works at: <https://commons.und.edu/pas-grad-posters>



Part of the [Medicine and Health Sciences Commons](#)

Recommended Citation

Swanson, Danielle M., "Benefits of 3D Breast Tomosynthesis Combined with 2D Digital Mammography in Screening Women for Breast Cancer" (2019). *Physician Assistant Scholarly Project Posters*. 234.
<https://commons.und.edu/pas-grad-posters/234>

This Poster is brought to you for free and open access by the Department of Physician Studies at UND Scholarly Commons. It has been accepted for inclusion in Physician Assistant Scholarly Project Posters by an authorized administrator of UND Scholarly Commons. For more information, please contact und.common@library.und.edu.

Benefits of 3D Breast Tomosynthesis Combined with 2D Digital Mammography in Screening Women for Breast Cancer

Danielle M. Swanson PA-S

Department of Physician Assistant Studies, University of North Dakota School of Medicine & Health Sciences

Abstract

- Breast cancer screening imaging options have progressed greatly over the years in sensitivity, specificity, and image quality. According to DynaMed Plus, in 2012 there were 522,000 deaths by breast cancer and 1,677,000 total cases of breast cancer documented (Dynamed, 2018). For years, traditional screening for breast cancer involved 2D digital mammography which obtains two views of each breast. With advances in technology, the use of 3D breast tomosynthesis has become an advantageous addition to routine breast cancer screening protocols at many health care facilities.
- My literature review of articles was found in PubMed, DynaMed Plus, Cochrane Library, and Clinical Key from the year 2011 and on. The benefits of 2D digital mammography alone, 3D breast tomosynthesis alone, and 2D digital mammography combined with 3D breast tomosynthesis are compared. This study also compares the differences in radiation dose of each imaging option. The research demonstrated that 2D digital mammography combined with 3D breast tomosynthesis offers the lowest recall rates, the highest sensitivity and specificity, and increases the effectiveness of breast cancer screening.
- Key Terms: breast cancer screening, age 40 and older, 2D mammography, 3D mammography, and radiation dose mammography.

Introduction

- 2D digital mammography has been considered the gold standard for breast cancer screening (Dynamed, 2018). Each healthcare facility develops its own protocol for breast cancer screening. Some facilities have the resources to combine 2D digital mammography with 3D breast tomosynthesis in one imaging system.
- 2D digital mammography consists of two views of each breast under compression. 3D breast tomosynthesis consists of the same views under compression for each breast. During 3D breast tomosynthesis, the patient is under compression while the machine moves in a semi-circular pattern to obtain many views from different angles. While the machine rotates around the breast obtaining these different views, it is ultimately capable of imaging the breast tissue with minimal superimposition. This is very helpful in patients who have dense breast tissue in which cancer can easily hide. The digital ability of the 3D breast tomosynthesis machine reconstructs the two views that are normally obtained by 2D digital mammography. There is question as to whether the reconstructed views obtained by 3D breast tomosynthesis are diagnostically comparable to those obtained by 2D digital mammography.
- The purpose of this study is to compare the specificity, sensitivity, and radiation dose of 2D digital mammography alone, 3D breast tomosynthesis alone, and 2D digital mammography combined with 3D breast tomosynthesis. This study involves screening in women age 40 and older for breast cancer. The sensitivity and specificity of the imaging options weighs heavily on whether a patient is called back for further imaging, studies, or procedures.
- Reducing the number of call backs for patients is beneficial to the patients, their loved ones, and the institution in which the patient doctors.

Statement of the Problem

- When a patient receives a 3D breast tomosynthesis scan, it can reconstruct images that a 2D digital mammography scan would provide. This could ultimately eliminate the need for 2D digital mammography. Further investigation is needed to determine the specificity, sensitivity, and radiation dose of 2D digital mammography, 3D breast tomosynthesis, and these studies combined. This will help determine the safest and most effective imaging protocol for screening of breast cancer as this is an annual recommendation.

Research Question

- In women age 40 and older, does screening for breast cancer using 3D breast tomosynthesis alone versus 2D digital mammography alone offer increased accuracy, specificity, sensitivity, and less call back tests for patients?
- In women age 40 and older, does screening for breast cancer using combination of 2D digital mammography with 3D breast tomosynthesis versus 2D digital mammography alone or 3D breast tomosynthesis alone offer increased accuracy, specificity, sensitivity, and less call back tests for patients?

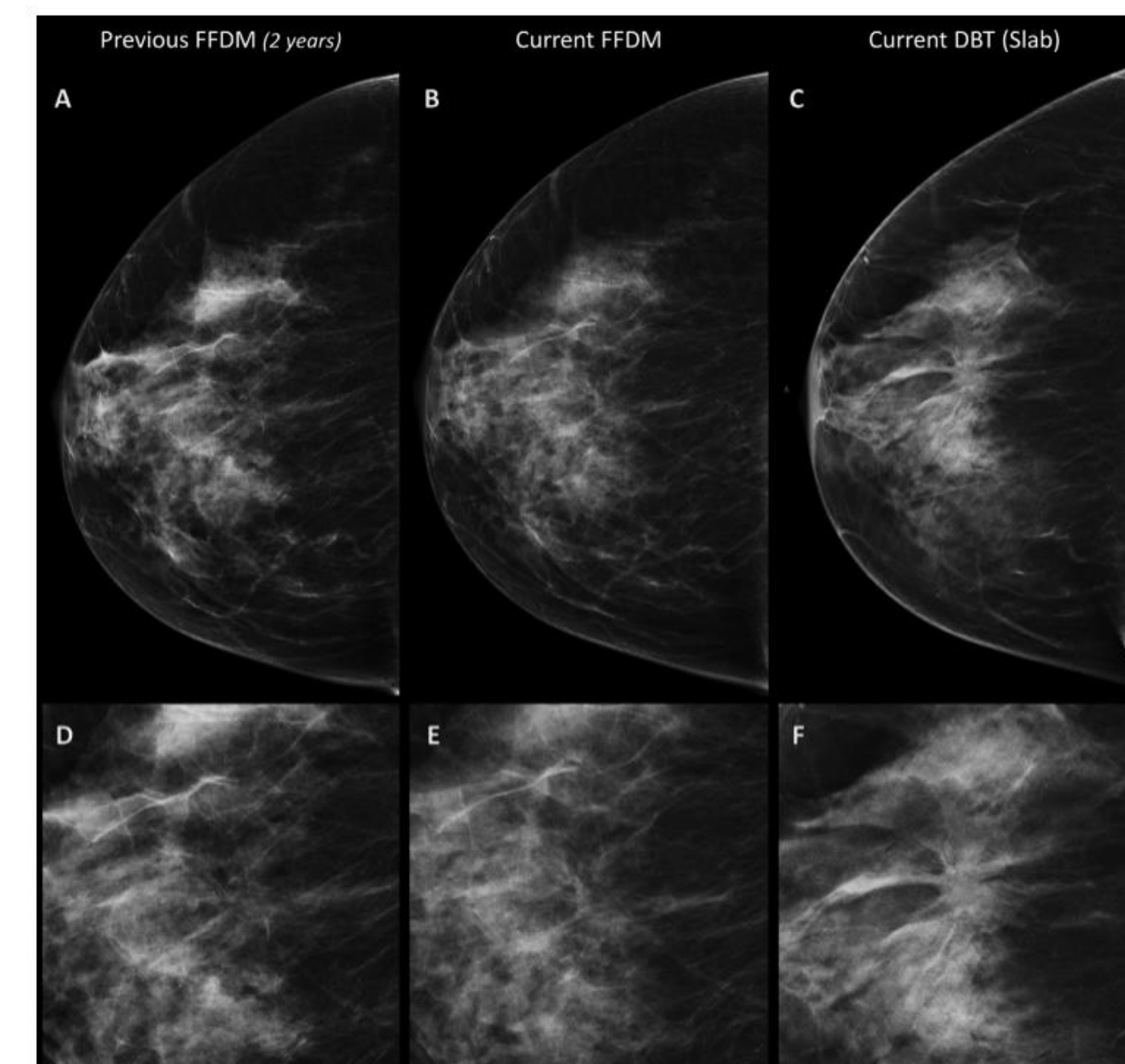
Literature Review

- Current screening recommendations and imaging options for breast cancer
 - At least every two years for average-risk women aged 50-74. Patients offered screening at age 40; this is based on shared decision making. Mammography is the imaging of choice for patients with average-risk of breast cancer. (Dynamed, 2018).
 - A limitation to this study is that it does not discuss the radiation doses of each imaging modality.
 - The American College of Radiology (ACR) Appropriateness Criteria for Breast Cancer Screening recommends annual screening mammography or 3D breast tomosynthesis for average-risk women age 40 and older (Mainiero et al., 2017).
 - A limitation to this study is the lack of evidence of cancer detection rates in each imaging modality.
- Comparing 2D digital mammography alone and 3D breast tomosynthesis (with 2D reconstruction) alone
 - Recall rate for 3D breast tomosynthesis was 3.0% and 3.6% for 2D digital mammography (Aase et al., 2018).
 - There were a moderate number of cases included in the study which represents a limitation especially when stratifying into subgroups.
 - Recall rate for women with dense breasts was 2.2% for 3D breast tomosynthesis and 3.4% for 2D digital mammography (Aase et al., 2018).
 - Sensitivity, specificity, PPV, and NPV of 3D breast tomosynthesis (0.93, 0.75, 0.64, 0.96) were higher than 2D digital mammography (0.90, 0.56, 0.49, 0.92). It was concluded that there was a significant reduction in the need for additional views with 3D breast tomosynthesis (Mall et al., 2018)
 - Limitation of the study is the fact that 144 participants is relatively small.
- Comparing 2D digital mammography combined with 3D breast tomosynthesis
 - There was an increase in cancer detection for 3D breast tomosynthesis plus 2D digital mammography than 2D digital mammography alone for invasive cancer, stage T1, nodal-negative, all histologic grades, and histologic types of invasive cancer. Combining 3D breast tomosynthesis with 2D digital mammography did not increase detection of carcinoma in situ or nodal-positive cancer. (Yun et al., 2017).
 - A limitation to this study is that the radiation doses were not included based on the lack of evidence they were able to find from the studies selected to review.
 - Detection rate was about 90% higher with 3D breast tomosynthesis combined with 2D digital mammography than with 2D digital mammography alone (Pattacini et al., 2018).
 - A limitation was that the study's read time was estimated for digital mammography and for digital breast tomosynthesis but not for these studies combined as this occurred after reading digital breast tomosynthesis alone.
- Comparison of radiation doses between 2D digital mammography alone, 3D breast tomosynthesis alone, and 2D digital mammography combined with 3D breast tomosynthesis
 - Estimated mean glandular dose (per view) was 1.36mGy for 2D digital mammography, 1.87mGy for 3D breast tomosynthesis, and 3.22mGy for a combination study (Gennaro et al., 2017).
 - The examinations were all performed on the same system (Selenia Dimensions Hologic) which allows the study to be stable in terms of radiation dose delivered but this is also a limitation because different systems deliver a slightly different dosage.
 - Estimated mean glandular dose for 3D breast tomosynthesis was 2.96mGy and 2.95mGy for 2D digital mammography (Aase et al., 2018)
 - Physicists work with imaging systems purchased by a health care facility in order to calibrate them appropriately.

Discussion

- In women age 40 and older, does screening for breast cancer using 3D breast tomosynthesis alone versus 2D digital mammography alone offer increased accuracy, specificity, sensitivity, and less call back tests for patients?
 - Mall et al. (2018) reported that 3D breast tomosynthesis demonstrates increased sensitivity, specificity, positive predictive value, and negative predictive value when compared to 2D digital mammography. It also included that radiologists had improved performance when reading 3D breast tomosynthesis compared to 2D digital mammography. In conclusion of the study conducted by Mall et al. (2018), 3D breast tomosynthesis is superior to 2D digital mammography and reduces the need for additional views which increases the patient's radiation exposure.
 - According to Gennaro et al. (2017) and Mainiero et al. (2018), there is only a modest increase in radiation dose when replacing 2D digital mammography with 3D breast tomosynthesis. It is important to mention that the radiation dose is different for each imaging system used and depends on how the machine is calibrated by the facility's physicists.
- In women age 40 and older, does screening for breast cancer using combination of 2D digital mammography with 3D breast tomosynthesis versus 2D digital mammography alone or 3D breast tomosynthesis alone offer increased accuracy, specificity, sensitivity, and less call back tests for patients?
 - When 3D breast tomosynthesis is combine with 2D digital mammography instead of digitally constructing the views obtained by 2D digital mammography, this results in higher invasive cancer detection rates and increased effectiveness of breast cancer screening making it the superior screening protocol (Hodgson et al., 2016).
 - Overall, the review of the literature demonstrates that the combination of 3D breast tomosynthesis and 2D digital mammography provides the most accurate detection of breast cancer and the highest specificity, sensitivity, positive predictive value, negative predictive value, and the lowest recall rate for further imaging. The only risk and negative side to this combination being standard screening, is a modest increase in radiation dose and a slight increase in time that the patient is under compression.

Figure 1: 70-year-old woman's imaging comparing FFDM (2D digital mammography) with DBT (3D breast tomosynthesis). This demonstrates the imaging quality of invasive ductal carcinoma in craniocaudal views accompanied by correlating magnification views.



Pattacini, P., Nitrosi, A., Giorgi Rossi, P., Iotti, V., Ginocchi, V., ... Ravaioli, S. (2018). Digital Mammography versus Digital Mammography Plus Tomosynthesis for Breast Cancer Screening: The Reggio Emilia Tomosynthesis Randomized Trial. *Radiology*, 288(2), 375-385. <https://doi.org/10.1148/radiol.2018172119>

Applicability to Clinical Practice

- When 3D breast tomosynthesis is combined with 2D digital mammography, the rate of patients who got called back for further imaging were lower than the rate compared to 2D digital mammography alone and 3D breast tomosynthesis alone. The greatest benefit of 3D breast tomosynthesis is the technology it uses to look at tissue in the breast without superimposition. This increase in specificity and sensitivity saves the patient from unnecessary anxiety, time taken out of their daily lives, and increased cost to the patient and healthcare facility. There have been instances where 3D breast tomosynthesis has saved a patient from addition procedures that, in some cases, can be invasive. This is especially important and significant in women with dense breast tissue. Cancer hides easily in dense breast tissue on 2D digital mammography.
- Some studies reported a slight increase in radiation dose when combining 3D breast tomosynthesis with 2D digital mammography while other studies did not report an increase in radiation. The radiation dose depends on the imaging system and the physicists who work together to calibrate the system in order to deliver a radiation dose as low as reasonably achievable. There are some imaging systems in which there is no increase in radiation dose when 3D breast tomosynthesis is combined with 2D digital mammography. This information is incredibly valuable to providers when ordering screening mammography studies for women. When a patient expresses concern about the added radiation or added compression they will undergo, the information included in this literature review helps to better explain the mammographic study including the risks and benefits
- If a health care facility's protocol for breast cancer screening involves 3D breast tomosynthesis combined with 2D digital mammography, evidence in this literature review shows that this offers the most accurate and safest imaging option for breast cancer screening in women 40 and older.

References

- Aase, H. S., Holen, Å. S., Pedersen, K., Houssami, N., Haldorsen, I. S., Sebuødegård, S., ... Hofvind, S. (2018). A randomized controlled trial of digital breast tomosynthesis versus digital mammography in population-based screening in Bergen: Interim analysis of performance indicators from the To-Be trial. *European Radiology*. <https://doi.org/10.1007/s00330-018-5690-x>
- Coop, P., Cowling, C., & Lawson, C. (2016). Tomosynthesis as a screening tool for breast cancer: A systematic review. *Radiography*, 22(3), e190-e195. <https://doi.org/10.1016/j.radi.2016.03.002>
- DynaMed. (2018). Breast cancer screening. Retrieved from <http://www.dynamed.com.ezproxylr.med.und.edu/topics/dmp-AN-T361086/Breast-cancer-screening#sec-Overview-and-Recommendations>
- Gennaro, G., Bernardi, D., & Houssami, N. (2017). Radiation dose with digital breast tomosynthesis compared to digital mammography: Per-view analysis. *European Radiology*, 28(2), 573-581. <https://doi.org/10.1007/s00330-017-5024-4>
- Hodgson, R., Heywang-Köbrunner, S. H., Harvey, S. C., Edwards, M., Shaikh, J., Arber, M., & Glanville, J. (2016). Systematic review of 3D mammography for breast cancer screening. *The Breast*, 27, 52-61. <https://doi.org/10.1016/j.breast.2016.01.002>
- Mainiero, M., Moy, L., Baron, P., Didwania, A., diFlorio, R., Green, E., ... Newell, M. (2017). ACR Appropriateness Criteria® Breast Cancer Screening. *Journal of the American College of Radiology*, 14(11), S383-S390. <https://doi.org/10.1016/j.jacr.2017.08.044>
- Mall, S., Noakes, J., Kossoff, M., Lee, W., McKessar, M., Goy, A., ... Mello-Thoms, C. (2018). Can digital breast tomosynthesis perform better than standard digital mammography work-up in breast cancer assessment clinic? *European Radiology*. <https://doi.org/10.1007/s00330-018-5473-4>
- Marinovich, M. L., Hunter, K. E., Macaskill, P., & Houssami, N. (2018). Breast Cancer Screening Using Tomosynthesis or Mammography: A Meta-analysis of Cancer Detection and Recall. *JNCI: Journal of the National Cancer Institute*, 110(9), 942-949. <https://doi.org/10.1093/jnci/djy121>
- Pattacini, P., Nitrosi, A., Giorgi Rossi, P., Iotti, V., Ginocchi, V., ... Ravaioli, S. (2018). Digital Mammography versus Digital Mammography Plus Tomosynthesis for Breast Cancer Screening: The Reggio Emilia Tomosynthesis Randomized Trial. *Radiology*, 288(2), 375-385. <https://doi.org/10.1148/radiol.2018172119>
- Yun, S. J., Ryu, C.-W., Rhee, S. J., Ryu, J. K., & Oh, J. Y. (2017). Benefit of adding digital breast tomosynthesis to digital mammography for breast cancer screening focused on cancer characteristics: A meta-analysis. *Breast Cancer Research and Treatment*, 164(3), 557-569. <https://doi.org/10.1007/s10549-017-4298-1>